Stratified epithelium:

The stratified epithelial tissue is made of more than one layer of cells and classified according to the cell shape of its superficial layers in to:

1- Squamous 2. Cuboidal 3. Columnar 4. Transitional.

These typically are at sites needing a more defensive, rather than a metabolic function.

1- Stratified Squamous Epithelial Tissue:

Composed of many layers of cells, the basal layer composed of columnar or cuboidal cells, the middle cell layers composed of polygonal cells, and the superficial layer is a squamous cells.

There are 2 types of stratified squamous epithelium:

A- Stratified Squamous Non- Keratinized Type:

It lines the moist cavities of the mouth. This exhibit live superficial cells contain nuclei. Found in areas requiring protection such as esophagus, anal canal and vagina. the cells at the surface are very flattened as opposed to the nearly columnar basal cells. Surface cells are continuously lost and replaced by cell division in deeper layers.

B- Stratified Squamous Keratinized Type:

It lines the dry areas like the skin and contains non- living cells rich with keratin intermediate filament and containing no nucleus. found mainly in the epidermis of skin.

variety forms , Its cells form many layers , and the cells closer to the underlying connective tissue are usually cuboidal or low columnar The cells become irregular in shape and flatten as they accumulate keratin in the process of keratinization - moved progressively closer to the surface where they become thin.

contains protein keratin. waterproof, resistant to friction, helps repel bacteria . metabolically inactive squamous , keratin lacking nuclei this surface layer of cells helps protect against water loss across this epithelium

2-Stratified Cuboidal Epithelium:

consists of several layers of cells in which the top layer is cub shaped, the nuclei are large and central, is found in large excretory ducts of sweat glands , salivary glands, vesicular (Graafian) follicles of ovary, sebaceous glands and mammary glands.

3- Stratified Columnar Epithelium:

Several layers of cells in which the top layer is rectangular - Basal layer cells are short irregular and poly hydral .It is present only in small areas in the human body such as the largest ducts of exocrine glands. The basal cells either cuboidal or columnar shape.found in lining of the eye lids, Small amounts in pharynx, male urethra, and lining some glandular ducts and also occurs at

transition areas between two other types of epithelia. The function of this type Secretion and protection Location

4- Transitional Epithelium:

Is found exclusively in the excretory passages of the urinary system. It lines the urinary bladder, ureter, and the upper part of the urethra. The basal layer cells are small polygonal or short columnar. The middle layer cells are pyramidal, while the superficial layer cells are large, with umbrella shaped or dome like cells, and sometimes are binucleated.

This type of tissue has the ability to rearrange the number of the cell layers, depending on whether it is in a distended or contracted state. e.g. in the contracted bladder, the epithelium consists of 5-6 layers and the cells are dome shaped while in distended bladder, the tissue is made up of 2-3 layers, the superficial layer is composed of large squamous cells, but only the basal one is composed of cuboidal cells.

Basement membrane

Epithelial tissue rests on a basement membrane, which acts as a scaffolding on which epithelium can grow and regenerate after injuries Epithelial tissue has a nerve supply, but no blood supply and must be nourished by substances diffusing from the blood vessels in the underlying tissue.

Special Features of Epithelium :

1-cilia : (singular= cilium, Latin= eyelash) - hair-like appendages attached to the apical surface of cells that act as sensory structures or to produce movement .

2-Goblet cells : Specialized cells that produce mucus to lubricate and protect the surface of an organ .

3-Villi : (singular= villus, Latin= shaggy hair)- finger-like projections that arise from the epithelial layer in some organs. They help to increase surface area allowing for faster and more efficient absorption .

4-Microvilli : Smaller projections that arise from the cell's surface that also increase surface area. Due to the bushy appearance that they sometimes produce, they are sometimes referred to as the brush border of an organ.

Glandular tissue

Glandular tissue is the type of epithelium that forms the glands from the in folding of epithelium and subsequent growth in the underlying connective tissue. There are two major classifications of glands: endocrine glands and exocrine glands:

•Endocrine glands secrete their product into the extracellular space where it is rapidly taken up by the blood vascular system.

•Exocrine glands secrete their products into a duct that then delivers the product to the lumen of an organ or onto the free surface of the epithelium.

Development Of Epithelial Tissues:

Epithelial tissues are derived from all of the embryological germ layers
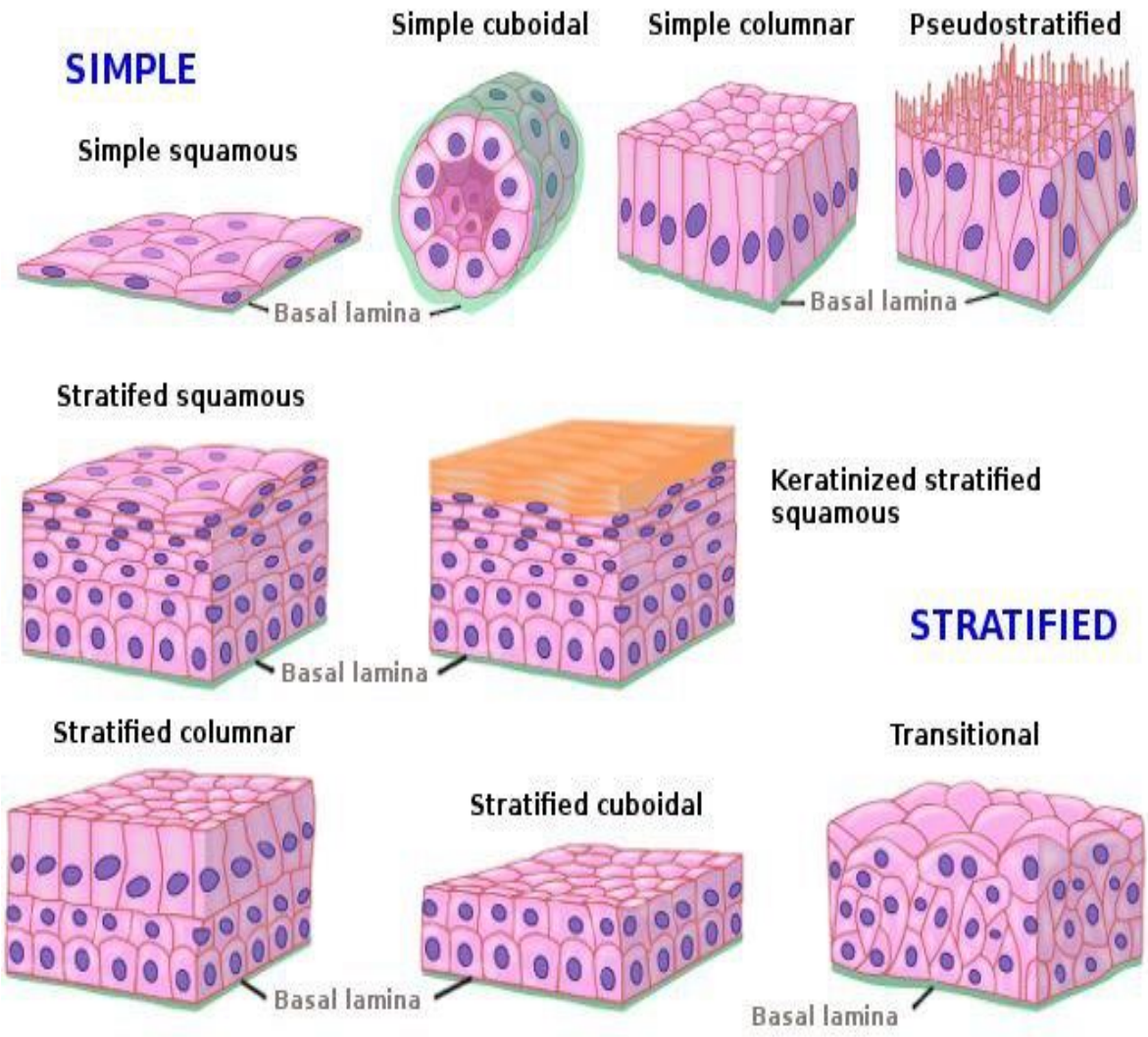
- from ectoderm (e.g., the epidermis)
- from endoderm (e.g., the lining of the gastrointestinal tract)
- from mesoderm (e.g., the inner linings of body cavities).