Macrocytic anemia:

The RBCs are large in peripheral blood with high MCV.

They can be divided into megaloblastic (Folate or B12 deficiency) and non-megaloblastic anemia (as in alcoholism, liver disease, hypothyroidism, drugs, aplastic anemia, pregnancy, neonate and smoking).

Megaloblastic anemia:

The megaloblastic anemia is characterized by the presence of distinctive morphological appearances of the developing red cells in the bone marrow (Megaloblasts).

The cause is deficiency of either cobalamin (vitamin B12) or folate.

Dietary sources and absorption:

Folic acid is found in most foods. The principal site of folate absorption is the upper small intestine.

Cobalamin is synthesized solely by micro-organisms, and the only source of it is food of animal origin.

Absorption of B12 occurs through the ileum and is mediated by gastric intrinsic factor (IF) which is secreted by gastric parietal cells. IF attaches to a specific receptor in the ileum. Then absorbed cobalamin in blood is transported attached to transcobalamin protein.

Biochemical basis of megaloblastic anemia:

The common feature of megaloblastic anemias is a defect in DNA synthesis that affects rapidly dividing cells in the bone marrow.

All conditions that give rise to megaloblastic changes share in common a disparity in the rate of synthesis of the four immediate precursors of DNA, the deoxyribonucleoside triphosphate (dNTP): adenine (dATP) and guanine (dGTP) (which are purines), and thymine (dTTP) and cytosine (dCTP) (which are pyrimidines) required for DNA replication.

In folate or cobalamin deficiency, the defect in DNA synthesis is caused by a failure to convert adequate amounts of deoxyuridine monophosphate (dUMP) to deoxythymidine monophosphate (dTMP). This is because folate is needed as the coenzyme 5,10-methylene tetrahydrofolate polyglutamate (THF as Methyl donor) for conversion of dUMP to dTMP and the availability of this coenzyme is reduced in either cobalamin or folate deficiencies.

All cells in the body receive folate from plasma as methyl THF, and B12 is needed in conversion of methyl THF to THF (a reaction in which homocysteine is methylated to methionine). THF (and not methyl THF) is the substrate for folate polyglutamate synthesis inside the cell.

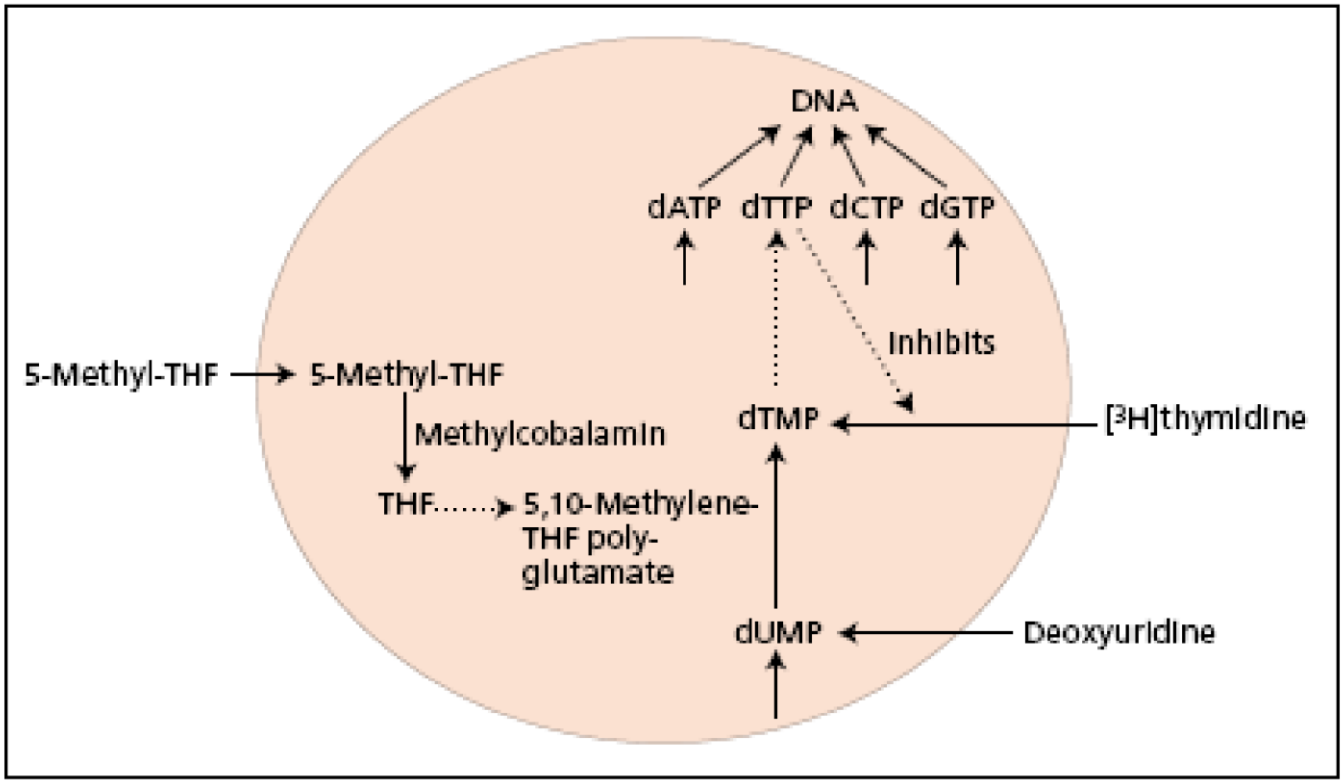
DNA
dATP
dTTP
dCTP
dGTP
Inhibits
5-Methyl-THF
5-Methyl-THF
Methylcobalamin
dTMP
[3H]thymidine
THF
5,10-Methylene-THF poly-glutamate
dUMP
Deoxyuridine

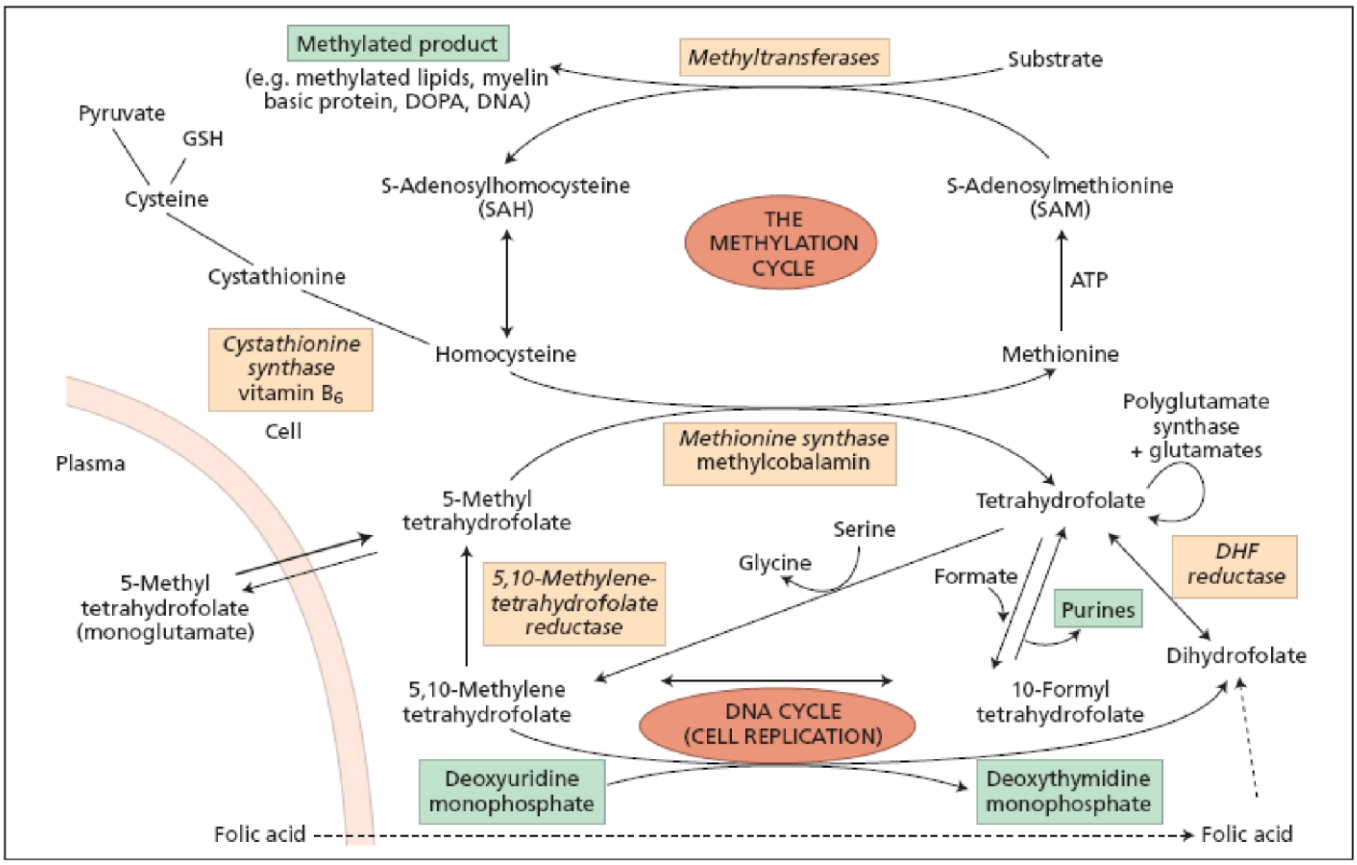
Methylated product
(e.g. methylated lipids, myelin basic protein, DOPA, DNA)
Methyltransferases
Substrate
Pyruvate
GSH
Cysteine
S-Adenosylhomocysteine (SAH)
THE METHYLATION CYCLE
S-Adenosylmethionine (SAM)
Cystathionine
ATP
Cystathionine synthase vitamin B6
Homocysteine
Methionine
Cell
Plasma
Polyglutamate synthase + glutamates
Methionine synthase methylcobalamin
5-Methyl tetrahydrofolate
Tetrahydrofolate
Serine
Glycine
DHF reductase
5-Methyl tetrahydrofolate (monoglutamate)
5,10-Methylene-tetrahydrofolate reductase
Formate
Purines
Dihydrofolate
5,10-Methylene tetrahydrofolate
DNA CYCLE (CELL REPLICATION)
10-Formyl tetrahydrofolate
Deoxyuridine monophosphate
Deoxythymidine monophosphate
Folic acid
Folic acid

Hematological findings: The severity of all the following changes parallels the degree of anemia;

- Hemoglobin and PCV are low.
- Peripheral blood: Oval macrocytes with anisocytosis and poikilocytosis. Some of the neutrophils are hypersegmented (more than five nuclear lobes). Together, macrocytosis and hypersegmentation, are strongly suggestive of megaloblastic hemopoiesis. There may be leucopenia. Platelet count may be reduced.
- MCV is usually > 100 fl.
- Raised red cell distribution width (RDW).
- Low serum vitamin B12 in cobalamin deficiency.
- Low serum and red cell folate in folic acid deficiency.
- Bone marrow: the marrow is hypercellular and there is an accumulation of primitive cells due to selective death of more mature forms, i.e., ineffective erythropoiesis. Megaloblasts are the most characteristic finding, which show dissociation between nuclear and cytoplasmic development in the erythroblasts, with the nucleus maintaining a primitive appearance despite maturation and hemoglobinization of the cytoplasm. The nucleus of the megaloblast has an open, fine, lacy appearance, i.e., primitive appearance; the cells are larger than normoblasts. Giant metamyelocytes are characteristic.

Management of megaloblastic anemia:

(i) Identification and treatment of the underlying cause.
(ii) Correction of the deficient vitamin.
(iii) Prophylactic folic acid treatment in pregnancy, premature baby, hemolytic anemias and dialysis.
(iv) Prophylactic B12 treatment in gastrectomy and ileal resection.