Msc/sabah jabbar

- *Plasmodium vivax*
- *Plasmodium malariae*
- *Plasmodium falciparum (Most violent)*

Plasmodium (*Parasite*) —*infects*→ Female *Anopheles* Mosquito —*bites and infects*→ Humans

P.vivax

* The infected RBC contain fine dots (seimffner's dots)

* Primarily invade reticulocytes (young red cells).

Trophozoite

Ring stage: (early or young trophozoite)

* The size of the ring is large nearly equals (1/3-1/2) diamante of the RBC.

Amoeboid stage: (late or old trophozoite)

Is very pleomorphic, as the trophozoite grows it become irregular

* It fills over 1/2 the size of the enlarged RBC

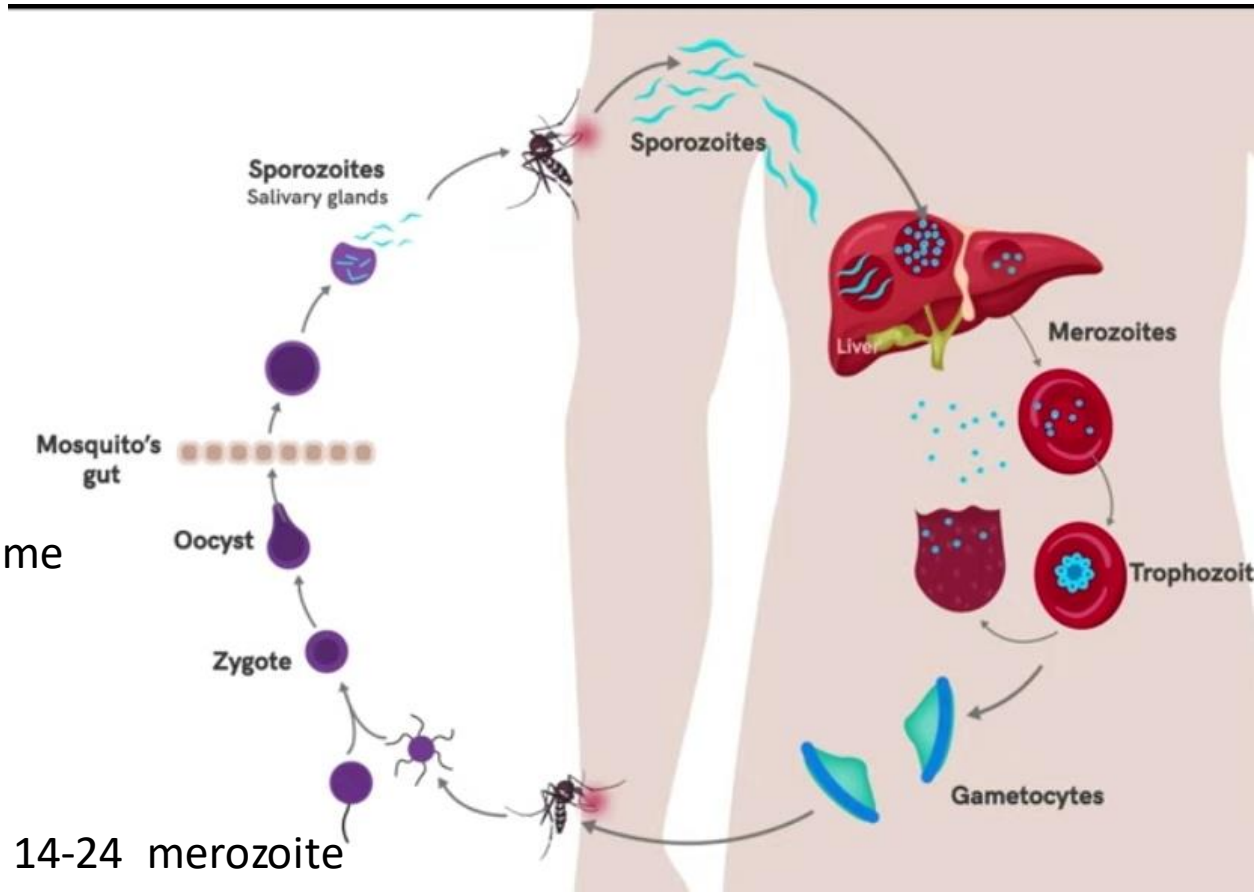

b. Schizont:

* In P. vivax each mature schizont contain more than 14-24 merozoite

c.gametocytes:

* They are round or oval, nearly fill the erythrocyte.

Plasmodium falciparum

* Multiple infection of the RBC is a common characteristic. It can invade all the red cell **(of all ages)**.

Only the ring forms & gametocytes are ordinary seen in peripheral blood.

i. **Ring stage** (early or young trophozoite):

Small ring in size (1/5 the RBC diameter).

* It may contain double chromatin dots (nuclei).* Multiple infection is common. May adhes to the RBC surface from the in side.

ii. Old (late) trophozoite: * Compact & rounded (not amoeboid)

b. Schizont:

* Resemble (similar) to that of P. vivax but not seen or very rare in peripheral blood (in blood of deep tissues). * Mature schizont usually contain more than (18-32) merozoite.

c. Gametocytes:

* Crescent in shape, stretching the corpuscular covering (elliptical). * When fully developed they have a characteristic banana shape, they so called crescent.

Plasmodium Malarias

* Infected RBC is not enlarged & no dots.
* **Primarily invade old RBC.** * All the forms of development can be seen in peripheral blood.

a. Trophozoite:

i. Ring stage (early Trophozoite): * The size of the ring is large nearly equals ~ 1/3 the size of RBC.

b. Schizont: * Mature schizont almost fills the unenlarged RBC.* Mature schizont usually contain 8-10 merozoite.

c. Gametocytes: * Are similar to those of P. vivax but are smaller & contain less pigment.

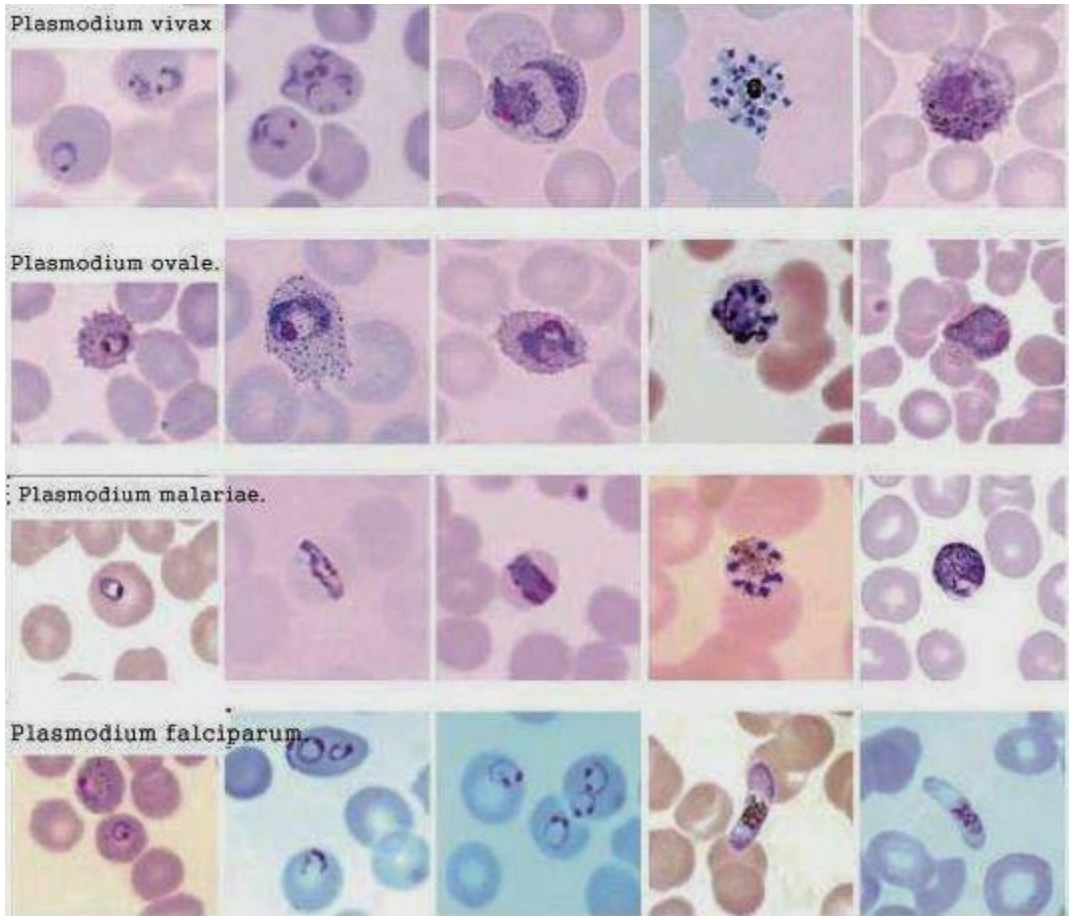

Laboratory diagnosis of malaria

Peripheral Blood —> blood film

1. Thin blood film : stain by leishman.

2. Thick: blood film: stain by geimsa.

Microscopic examination for erythrocytic stages.

Notes:

* Thin blood film: for differentiating species & stages. * Thick blood film: chance of detecting malarial parasites is larger. * Blood film should be done repeatedly * Misdiagnosis & difficulties in diagnosing malaria.

1. Dirty slide. 2. Stain (not filtered). 3. old specimen. 4. If the patient in severely anemic. 5. If the patient is on treatment

Serologicall diagnosis:

* ELISA & RIA (Radio Immune Assay). * Only in sui^vey & in checking blood from blood donors.