Histology

Digestive system

baneen Falih.

The digestive system

The digestive system of a fetus consists of four main parts: the *esophagus, the stomach, the small intestine, and the large intestine, which ends in the rectum.* The wall of each of these parts consists of four main layers that differ in nature and thickness with the requirements of the function performed by these parts. The layers, starting from the inside to the outside, are as follows:

1- The mucosa layer, and this layer, in turn, includes parts The next third:

A- The mucosa muscularis, which is a thin layer of smooth muscle cells and elastic fibers.

B- layer loose connective tissue known as the propria lamina

c- lining epithelium and forms the inner part of the mucous layer that It faces the inner part of the alimentary canal.

2- The submucosa, which is the second layer of the alimentary canal.

3- Layer externa muscularis

4 - adventitia.

The alimentary canal has a structure consistent with its functions The muscular part of the canal works to mix the contents and push it to the buttocks, and it is also equipped with glandular elements that secrete fluids and enzymes necessary for chemical reactions, and the epithelial lining is adapted for the absorption process. The alimentary canal is equipped with vessels Blood and lymphatics that nourish their tissues, provide them with oxygen, get rid of carbon dioxide, and transport substances resulting from digestion.

esophagus

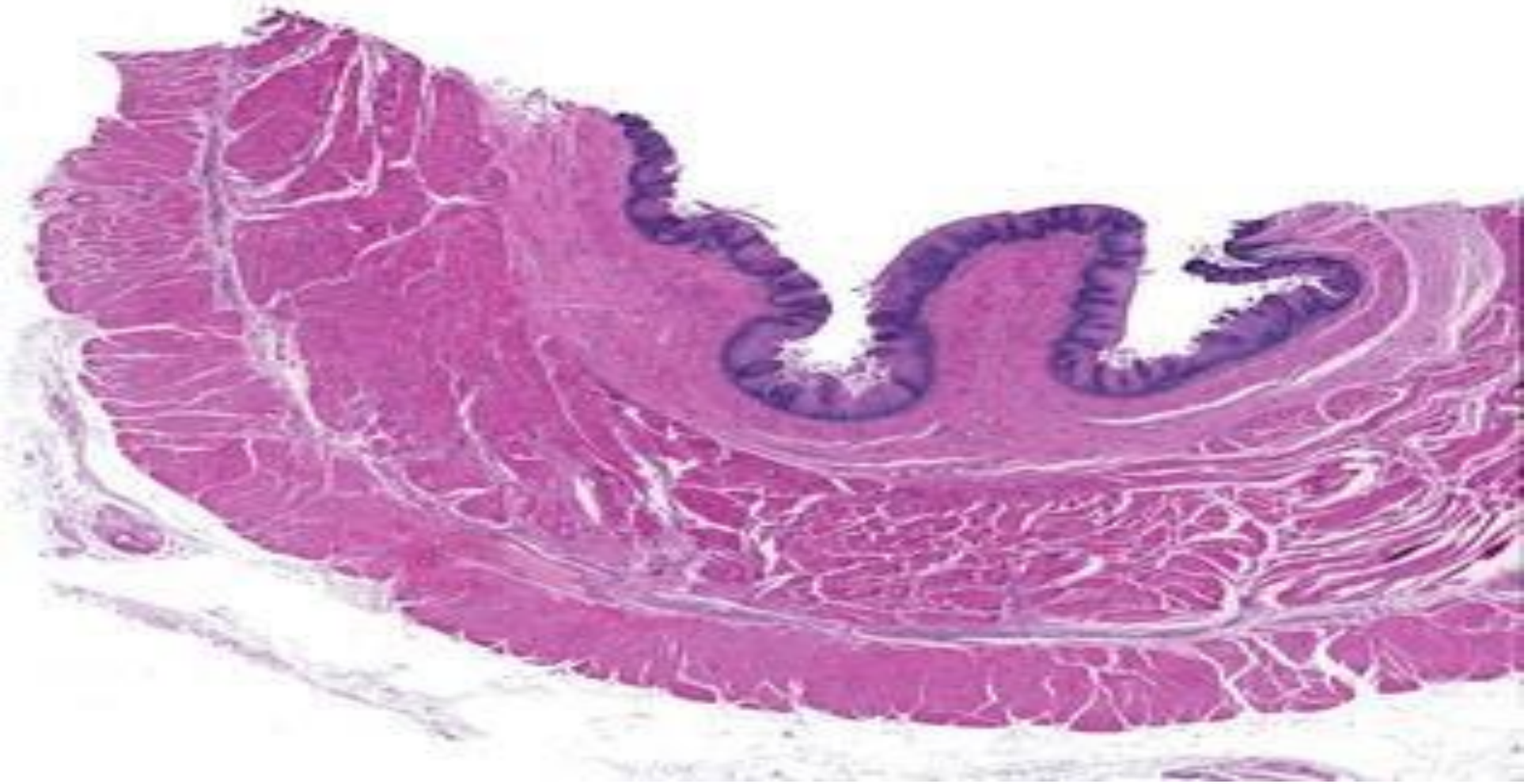

stomach

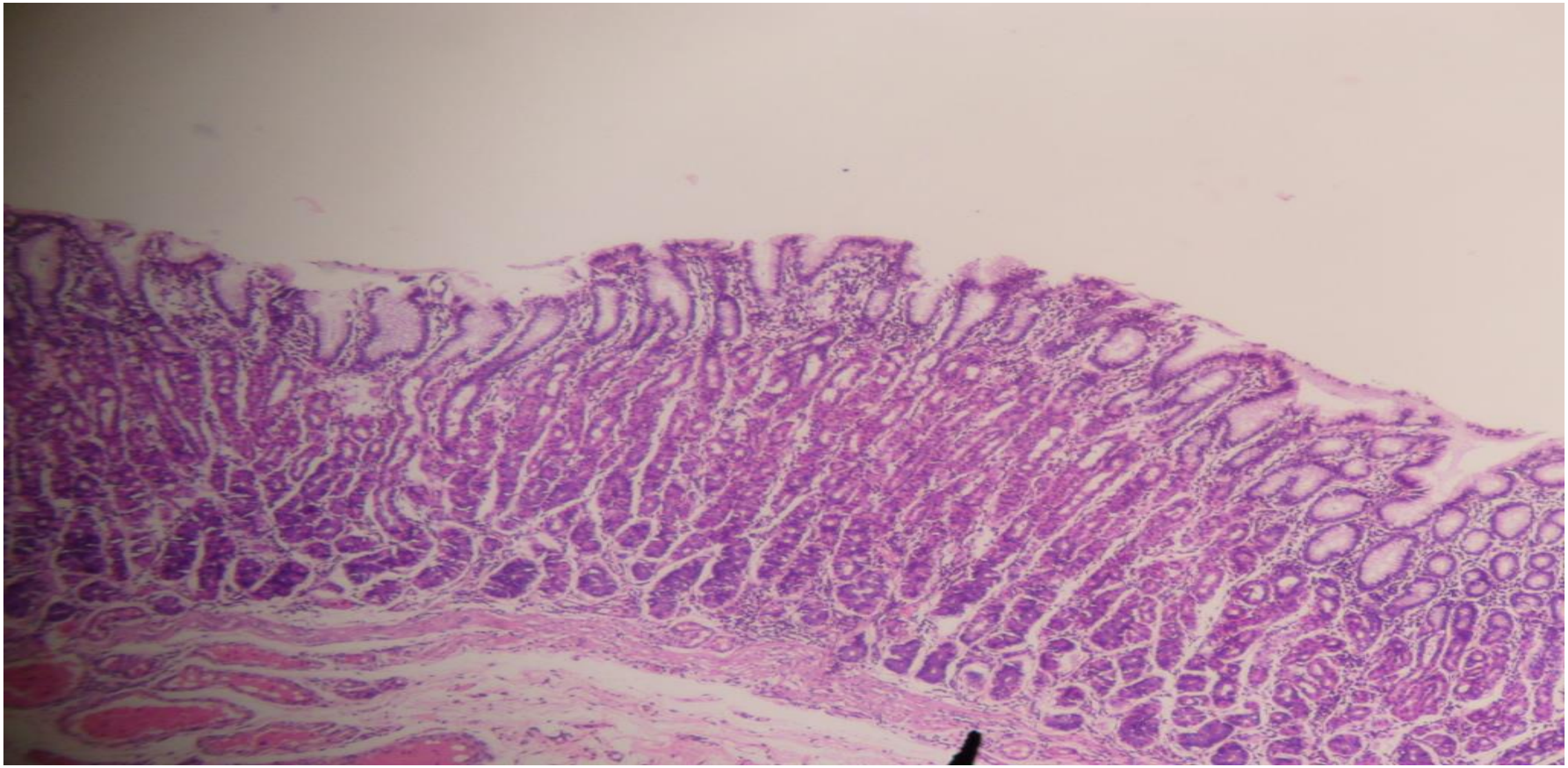

small intestine

Duodenum

Jejunum

Ileum

large intestine

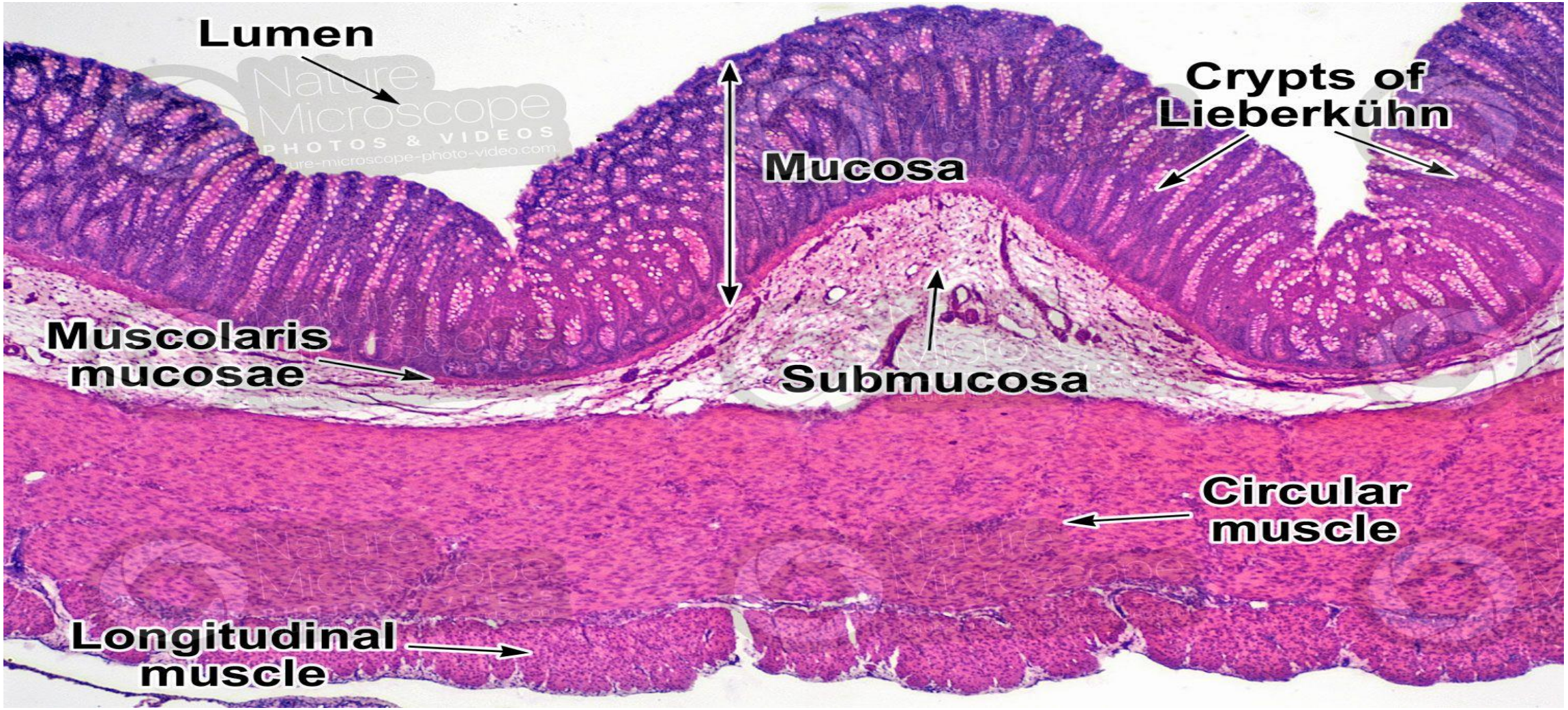

large intestine

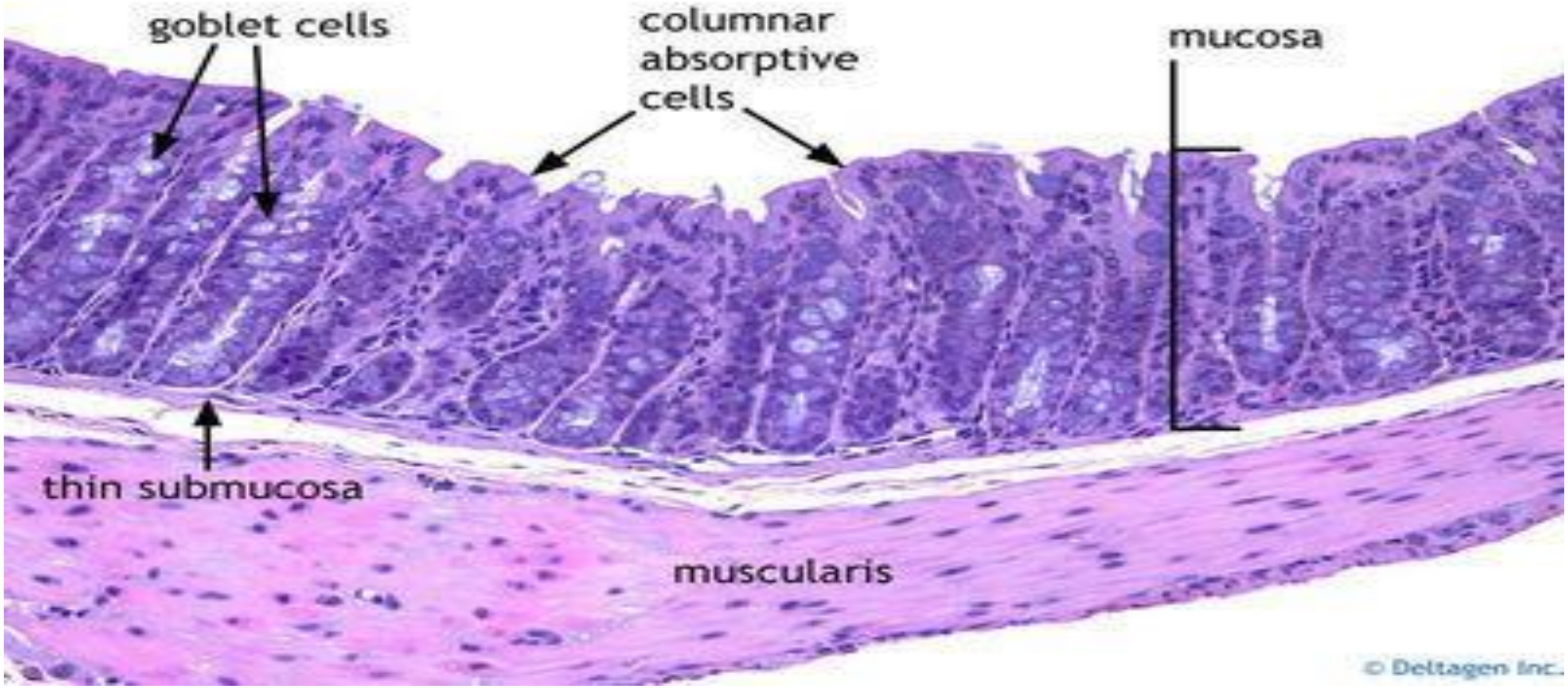

rectum

Rectum
Recto-anal junction
Anus
External anal sphincter (striated muscle)
Levator ani (striated muscle)
Inferior rectal vessels